

A Cone Beam Computed Tomography (CBCT) Analysis of Mental Foramen Location, Prevalence of Anterior Loop and Extension of Anterior Loop in the Local Population of Lahore: A Cross-Sectional Study

Ali Kamran, Abdul Mueed Zaigham, Khalid Yaqub

Department of Prosthodontics, Institute of Dentistry CMH Lahore Medical College, Lahore, Pakistan

Abstract

Background: Precise localization of the mental foramen (MF) and variations of the anterior loop (AL) of the inferior alveolar nerve are critical for safe implant placement, endodontic surgery, and mandibular osteotomy, yet population-based CBCT data in Pakistani individuals remain limited.

Objectives: To recognize distribution of MF zones, prevalence and frequency of the AL, demographic relationships, and bilateral symmetry in a local Pakistani population through CBCT.

Materials and Method: This cross-sectional study analyzed 217 CBCT scans (16–60 years), classifying MF into four zones (A–D), recording AL presence (absent/unilateral/bilateral) and measuring its deepest extension, with data analyzed using descriptive statistics, t-tests, ANOVA, chi-square, logistic regression, and McNemar–Bowker χ^2 tests ($p \leq 0.05$).

Results: On the right, the mental foramen (MF) was most frequent in Zones B and C (42.4% each), and on the left in Zone B (45.2%) and C (38.7%). The anterior loop (AL) was absent in 76% of scans, unilateral in 22.1%, and bilateral in 1.8%, with mean extensions of 3.05 ± 0.68 mm (right) and 3.12 ± 0.57 mm (left), showing no side, gender, or age differences ($p > 0.4$). MF Zone C inversely correlated with AL presence (OR = 0.29; $p = 0.022$), and significant left–right MF asymmetry was observed ($\chi^2 = 22.26$; $p = 0.001$).

Conclusion: In this Pakistani sample, the mental foramen was mostly between or near premolars with marked left–right asymmetry, while the anterior loop was rare (~3 mm when present), emphasizing the need for individualized CBCT assessment before interforaminal surgery.

Keywords (MeSH): Mental Foramen; Mandible; Cone-Beam Computed Tomography; Inferior Alveolar Nerve; Dental Implants.

Introduction

Proper knowledge of the anatomy of the mental foramen (MF) and anterior loop (AL) of the inferior alveolar nerve (IAN) is very important in dental and maxillofacial practice, particularly in preoperative planning in the interforaminal area of the mandible. The mental nerve traverses the MF and supplies the superficial lower lip, chin, and gingiva in front of the mental foramen.^{1,2} Variations in the position, shape, and pattern of emergence of the MF have been observed, which may complicate surgical exposure and lead to nerve injury unless adequately remedied by planning treatment.³

Anterior loop is a term referring to that part of the inferior alveolar nerve extending anteriorly beyond the MF prior to looping back in the foramen. In some, the nerve courses anteriorly and then reverse, creating a "safe" or "unsafe" buffer

zone that needs to be negotiated by the surgeon (first described by Bavitz et al.).⁴ Radiographically, its prevalence in different populations has been depicted extremely variable variation (ranging from ~11% to >50%) depending on imaging modality, population, and definition employed.⁵ The reported prevalence of the anterior loop of the inferior alveolar nerve is extremely variable, ranging from approximately 11% to more than 50%, contingent upon whether the imaging technique and population assessed are taken into account.

For example, a large CBCT-derived study had a combined prevalence of approximately 56% that was variable based on side, age, and gender (56% combined, 29% right side, 27% left side).⁶ Comparison with other prevalence studies shows lower prevalence rates of between approximately 11% using panoramic imaging and more than 50% using CBCT in different populations and ethnic groups.^{4, 7} The greater sensitivity of cone beam computed tomography (CBCT) over panoramic radiography is to be held accountable for the majority of increased prevalence findings reported in CBCT studies, as CBCT provides more accurate 3D visualization of nerve anatomy.^{6, 7} Two-dimensional imaging techniques (panoramic radiography, standard periapical films) are limited in their ability to reveal the AL accurately and precise MF position by distortion, superimposition, and magnification artifacts.

As systematic reviews have stated, panoramic radiography underestimates the frequency of loops or misrepresents the extent.⁸ Thus, cone-beam computed tomography (CBCT) is increasingly accepted as the gold standard for preoperative evaluation in the mandibular interforaminal area because of

Corresponding Author:

Ali Kamran

Department of Prosthodontics, Institute of Dentistry CMH
Lahore Medical College, Lahore

Email: sheikhalikamran66@gmail.com

Received: November 18, 2025

Revised: March 16, 2026

Accepted: March 18, 2026

DOI: <https://doi.org/10.52442/jrcd.v7i01.215>



This is an Open Access article distributed under the terms of the Creative Commons Attribution-Non Commercial 2.0 Generic License

three-dimensional, non-distorting imaging and greater visualization of thin anatomical structures.⁸ Nevertheless, with use of CBCT, printed prevalence and morphometrics of the AL and MF are vastly inconsistent across populations and demographic strata, most likely due to ethnic, developmental, and methodologic heterogeneity (e.g. image resolution, slice thickness, thresholding).

For instance,⁵ reported AL presence and morphometric correlations in an Indian population based on CBCT. In Pakistani local populations, very little research has been performed; for instance, a Karachi CBCT study reported variable MF positions and AL occurrence, noting region-specific morphometric information being a prerequisite.¹⁰ (Moreover, a new Lahore CBCT study measured MF positional variation relative to alveolar crest and mandibular border and found significant gender-based variability.¹¹)

Since its implications for safe surgical margins, placement implant planning, and procedure outcomes, region-specific data on MF zoning, AL frequency, loop extension length, and demographic associations are desperately needed. Herein, this study aimed to determine the prevalence of MF positions (by zone) in local population, frequency of the anterior loop (bilateral, unilateral, absent), the loop extension (mm) on each side and investigate variation between sides. Furthermore, the study explored possible correlations between loop presence or length and demographic variables (age and gender), as well as the bilateral symmetry of MF zones. In doing so, this study seeks to bridge the existing gap in morphological data for local population and to provide evidence-based, clinically relevant guidelines to enhance the safety and precision of implant placement and surgical planning within the interforaminal region of the mandible.

Materials and Method:

A retrospective consecutive sampling technique was used in this study. This cross-sectional study was performed in the Department of Prosthodontics, CMH Lahore Medical College and Institute of Dentistry, Lahore, Pakistan, after receiving approval from the institutional review board under ethical number 728/erc/cmh/lmc.

The CBCT scans included in the study were collected between June 2024 to November 2024. 217 cone-beam computed tomography (CBCT) scans of males and females of age 16-60 years were selected for treatment planning or diagnosis. The sample size was estimated using the formula for prevalence studies ($n = Z^2 \times P(1 - P) / d^2$) where Z represents the standard normal variate at a 95% confidence level (1.96), P represents the expected prevalence of the anterior loop based on previous CBCT studies (approximately 25%), and d represents the acceptable margin of error (5%). The minimum calculated sample size was approximately 200 scans. To improve statistical reliability and compensate for potential exclusions, a total of 217 CBCT scans were included in the final analysis.

The scans were incorporated only if there were permanent mandibular canine to first molar teeth bilaterally and the mental foramen (MF) was clearly visible. Scans with artifacts, previous surgery in the MF region, severe alveolar resorption, mandibular fracture, or supernumerary/impacted teeth were excluded. Cases of orthodontic appliances or anterior crowding were also not included, in compliance with earlier CBCT protocols.^{12,14} All CBCT images were taken with a standardized protocol (90 kV, 8 mA, 12 s exposure, voxel size 200 μ m, field of view 15.5 \times 8.1 cm) using a Planmeca ProMax® 3D Mid unit (Planmeca, Helsinki, Finland) and

were assessed using Romexis® software.

The MF was classified according to horizontal position into four zones (A–D) relative to premolar and molar apices^{8,15} as shown in figure 1.

Zone A: is in line with the apex of the first premolar
 Zone B: is between the apices of the first and second premolars.
 Zone C: is in line with the apex of the second premolar
 Zone D: is between the second premolar and the first molar

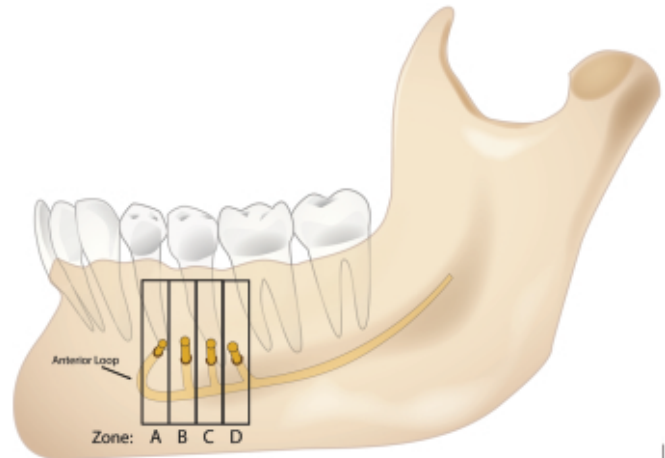


Figure 1: Classified position of mental foramen according to horizontal position into four zones (A–D) relative to premolar and molar apices

The presence of the anterior loop (AL) was considered when the inferior alveolar nerve extended anterior to the MF before curving posteriorly, and its extension was measured in millimeters along the deepest curve, according to validated CBCT protocols^{5,13}. Demographics, MF site, AL prevalence, and loop length were enumerated.

- (A) a line drawn parallel to the occlusal plane along the superior border of the mental foramen.
- (B) another line parallel to the mandibular lower border, corresponding to the inferior margin of the inferior alveolar nerve (IAN);
- (C) a line perpendicular to the occlusal plane intersecting the anterior border of the nerve loop.
- (D) a similar perpendicular line passing through the anterior border of the mental foramen.
- (E) the loop length measured along the trajectory of its deepest curvature.

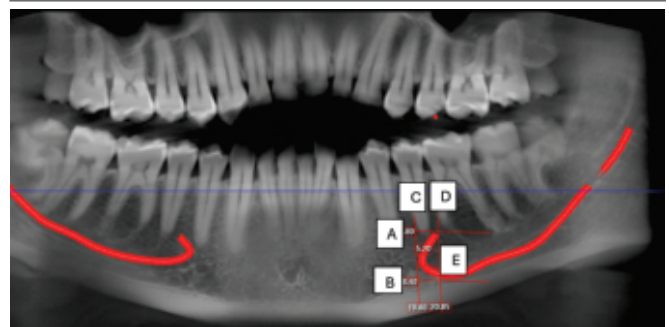


Figure 2: Schematic illustration showing the standardized reference lines used in this study for measuring the mental nerve loop.

All CBCT scans were evaluated by a single examiner with training in oral and maxillofacial radiology. The examiner was responsible for identifying the mental foramen position and measuring the anterior loop extension. Prior to the main analysis, the examiner underwent a calibration process using 20 randomly selected CBCT scans to standardise the identification of mental foramen and anterior loop measurement.

Statistical analysis was performed in SPSS v23.0 (IBM Corp., Armonk, NY, USA). Descriptive statistics were computed for all variables. Paired and independent t-tests, Welch's t-test, and one-way ANOVA were used to compare anterior loop length by side, gender, age, and MF zone. Chi-square and likelihood ratio tests examined associations of AL prevalence with demographic factors. Logistic regression was employed to identify predictors of the presence of loops, while bilateral symmetry of MF zones was tested using the Chi-square McNemar–Bowker. A p-value ≤ 0.05 was used as statistical significance, as per earlier CBCT-based Pakistani and other studies.^{10,14,16,17}

Results:

In 217 CBCT scans, the right MF was most frequently located in Zone B (42.4%) and Zone C (42.4%), with fewer cases in Zone A (6.5%) and Zone D (8.8%). On the left, the MF was most often observed in Zone B (45.2%) and Zone C (38.7%), with lower proportions in Zone A (9.2%) and Zone D (6.9%) (Table 1).

Table 1. Distribution of mental foramen (MF) locations, anterior loop prevalence, and demographics (N=217)

Variable	Category	N	%
Right Mental Foramen	Zone A	14	6.5
	Zone B	92	42.4
	Zone C	92	42.4
	Zone D	19	8.8
Left Mental Foramen	Zone A	20	9.2
	Zone B	98	45.2
	Zone C	84	38.7
	Zone D	15	6.9
Anterior Loop Prevalence	Both sides Present	4	1.8
	Right side only	31	14.3
	Left side only	17	7.8
	Absent	165	76.0
Gender	Male	86	39.6
	Female	131	60.4
Age Group	16–30 years	59	27.2
	31–45 years	80	36.9
	46–60 years	78	35.9
MF zones defined as Zone A = apex of first premolar; Zone B = between apices of first and second premolars; Zone C = apex of second premolar; Zone D = between second premolar and first molar.			

Anterior loops were absent in 76.0% of individuals. Loops were present unilaterally in 14.3% on the right and 7.8% on the left, while bilateral loops occurred in only 1.8% (Table 1).

Gender- and age-stratified analyses showed no significant associations. The likelihood ratio test suggested non-significant trends toward higher prevalence in younger groups and in males, but these did not reach significance (gender $\chi^2 = 6.06$, $p = 0.109$; age $\chi^2 = 7.13$, $p = 0.309$) (Supplementary Table S1).

Across all measurable loops, the mean extension was 3.05 ± 0.68 mm on the right ($n = 36$) and 3.12 ± 0.57 mm on the left ($n = 22$). Welch's independent samples t-test showed no significant side difference ($t(50.5) = -0.42$, $p = 0.675$).

Among six individuals with bilateral loops, the paired analysis showed right-side extensions of 3.24 ± 0.81 mm and left-side extensions of 2.87 ± 0.58 mm, with no significant difference (mean difference 0.37 mm; 95% CI -0.25 to 0.98 ; $p = 0.180$).

Table 2. Comparison of anterior loop extension between right and left sides

Comparison	N	Mean (mm)	SD (mm)	Test (df)	p-value
Right (all)	36	3.05	0.68	—	—
Left (all)	22	3.12	0.57	—	—
Right vs Left (Welch t)	—	—	—	$t(50.5) = -0.42$	0.675
Bilateral Right	6	3.24	0.81	—	—
Bilateral Left	6	2.87	0.58	—	—
Paired t-test	—	Diff=0.37	95% CI=0.25–0.98	$t(5)=1.54$	0.180

Anterior loop lengths varied minimally across MF zones. On the right, means ranged from 2.57 mm (Zone A) to 3.14 mm (Zone D); on the left, from 2.65 mm (Zone D) to 3.20 mm (Zone B). One-way ANOVA confirmed no significant differences (right: $F(3,32) = 0.678$, $p = 0.572$; left: $F(3,18) = 0.531$, $p = 0.667$).

Table 3. Mean anterior loop extension (mm) by mental foramen zone

Zone	Right Side		Left Side	
	(Mean \pm SD)	n	(Mean \pm SD)	n
A	2.57 \pm 0.63	2	2.98 (single case)	1
B	2.80 \pm 0.72	16	3.20 \pm 0.52	10
C	3.03 \pm 0.62	13	3.13 \pm 0.63	9
D	3.14 \pm 0.47	5	2.65 \pm 0.69	2
ANOVA results:	$F(3,32)=0.678$, $p=0.572$		$F(3,18)=0.531$, $p=0.667$	
ANOVA indicates no significant variation across zones. Low counts in Zones A and D may limit interpretation.				

Independent samples t-tests revealed no gender differences in loop extension (right: $p = 0.539$; left: $p = 0.920$). Similarly, one-way ANOVA showed no significant variation across age groups (right: $F(2,33) = 0.027$, $p = 0.974$; left: $F(2,19) = 0.887$, $p = 0.428$).

Binary logistic regression showed that the overall model was not statistically significant ($\chi^2(4) = 5.59$, $p = 0.134$). Among predictors, RMF Zone 3 (likely Zone C or D vs. reference) was significantly associated with reduced loop presence (OR = 0.29, 95% CI: 0.10–0.84, $p = 0.022$). Age showed a borderline trend toward reduced loop prevalence with increasing years ($p = 0.097$), while gender and left MF zone were excluded in earlier steps due to low significance.

Table 4. Logistic regression predicting anterior loop presence

Predictor	B	SE	Wald χ^2	P-Value	Exp(B)	95% CI for Exp(B)
RMF(1)	-0.649	0.761	0.727	0.394	0.523	0.118–2.322
RMF(2)	-0.752	0.527	2.036	0.154	0.471	0.168–1.325
RMF(3)	-1.246	0.545	5.227	0.022*	0.288	0.099–0.837
Age	-0.342	0.206	2.753	0.097	0.710	0.474–1.064
Constant	0.396	0.635	0.389	0.533	1.486	—

Reference categories: RMF Zone D; younger age group; female sex.

Cross-tabulation of right vs. left MF zones revealed significant asymmetry (McNemar–Bowker $\chi^2(6) = 22.26, p = 0.001$). For example, 13 participants had right Zone B but left Zone A, while only three showed the reverse. This highlights that MF locations are not reliably mirrored across sides.

Table 5. Cross-tabulation of right vs. left mental foramen zones

Left MF Zone	A	B	C	D	TOTAL
Right A	3	0	10	1	14
Right B	13	54	21	4	92
Right C	3	35	46	8	92
Right D	1	9	7	2	19
Total	20	98	84	15	217

McNemar–Bowker $\chi^2(6)=22.26, p=0.001$ (significant asymmetry).

Discussion

In this CBCT-based analysis of 217 mandibular scans, this study described MF zone distribution, prevalence and morphometry of AL, demographic correlates, and bilateral symmetry.

On both sides in our sample, the MF was found to be largely in Zone B and Zone C (each ~42 % on the right; 45.2 % and 38.7 % on the left). This trend follows that of most CBCT research across various populations indicating that the mental foramen is located most frequently between or aligned with the premolars (e.g. Shalash et al. in Egyptian sample identified the most frequent MF location below the apex of the second premolar).¹³ In Pakistani populations, Motiwala et al. (Karachi) also found that the MF was most commonly positioned along the long axis of the second premolar (52.1 % right, 51 % left).¹⁸ Nonetheless, our cross-tabulation and McNemar–Bowker test ($\chi^2 = 22.26, p = 0.001$) disclosed a significant asymmetry in MF location between left and right sides. Whereas other studies either have reported symmetry or have not discussed this matter, which is of high importance while planning for surgery and implant.

The anterior loop was not seen in 76 % of instances, seen unilaterally in ~22.1 % (14.3 % right only, 7.8 % left only), and in both sides in just 1.8 %. The observed prevalence of any anterior loop is therefore quite low. This is in contrast to many CBCT-based reports in the literature, which report higher loop prevalence. For instance, in a meta-analysis of 21 CBCT studies, pooled patient-level prevalence of AL was ~51 % (95 % CI: 31–71 %) and side-level ~53 % (95 % CI: 37–69 %).¹⁹ Hadilou et al. published an AL prevalence of ~36 % of hemimandibles and ~40.6 % of participants in CBCT studies (20). In an Indian study, Jena et al. reported that AL was "more often observed in males, mainly on the left side" in their sample.⁵

In the Karachi Pakistani sample, Motiwala et al. indicated anterior loop presence as relatively uncommon (3.2 % right, 5.2 % left).¹⁸, which resonates even lower than our prevalence. While, Rahim et al. (also in Pakistan) found AL in only 19 % of their 126-subject sample with mean extension ~3.9 mm on right and ~3.87 mm on left.¹⁴ Therefore, our lower prevalence could indeed represent real differences between populations, methodological thresholds (e.g. what is a "loop"), or imaging / measurement protocols (slice thickness, observer threshold). It highlights that average prevalence rates could overestimate loop occurrence in some populations, and that clinicians will need to exercise caution when extrapolating from one population to another.

Of the quantifiable loops, mean extension was 3.05 ± 0.68 mm (right, $n = 36$) and 3.12 ± 0.57 mm (left, $n = 22$); no significant side difference ($t = -0.42, p = 0.675$). In small bilateral subset ($n = 6$), right mean was 3.24 ± 0.81 mm versus left 2.87 ± 0.58 mm (paired t-test $p = 0.18$).

These measurements are slightly greater than the mean AL length of ~2.08 mm pooled in the meta-analysis.¹⁹ but fall within the wider ranges seen in separate studies. For instance, subgroup analyses by Hadilou presented mean values ~2.39 mm (95% CI: 2.07–2.70) in CBCT studies.²⁰ Srivastava et al. recently presented loop lengths in their sample of CBCTs too – albeit inconsistently according to side, region, and imaging conditions.²¹ When stratified by MF zone (e.g. right: 2.57 mm in Zone A to 3.14 mm in Zone D; left: 2.65–3.20 mm), loop extension did not differ significantly by zone (ANOVA $p > 0.5$). This suggest, once established, AL length is not highly regulated by MF horizontal zone, a conclusion repeated by some previous studies finding weak or inconsistent correlations between loop length and MF location (or proximal tooth position).

No gender difference was found in loop extension (right side: males 2.84 ± 0.64 mm vs females 2.98 ± 0.66 ; left side similar). One-way ANOVA also found no significant difference by age group. These null results are consistent with most of the CBCT literature, which tends to report weak or no correlation between AL presence/length and demographic factors (age, gender) in multivariate or pooled analyses (e.g. meta-analysis in Liuling Hui et al. identified no evident associations).¹⁹ A few single studies (e.g. Jena et al.) have noted mild male or side predilections but these do not hold across populations.⁵ In this study, only RMF Zone 3 (vs reference) was a statistically significant predictor (OR = 0.29, $p = 0.022$), suggesting that loops were less common in that region. The overall model was not statistically significant ($\chi^2 = 5.59, p = 0.134$), which indicates its limited predictive power. This hints at anatomical or developmental reasons not accounted for in our variables that might be better predictors of loop occurrence.

Clinical Implications: Accurate identification of the mental foramen (MF) and the anterior loop (AL) is crucial during implant placement in the interforaminal region because implant positioning that does not account for these anatomical variations may encroach upon the mental neurovascular bundle. Such positioning errors can result in direct trauma or compression of the mental nerve, leading to neurosensory complications including paresthesia, dysesthesia, or numbness of the lower lip and chin. The present findings demonstrate considerable variability in MF position and the presence of the anterior loop in the local population, which may increase the risk of neurosurgical injury if standard anatomical assumptions are used during surgical planning. The significant asymmetry observed in MF location further highlights that

clinicians should not rely on contralateral landmarks, as this may lead to inaccurate implant placement and potential nerve injury. Although the prevalence of anterior loops was relatively low, their mean extension of approximately 3 mm remains clinically important when determining safe implant distances. Therefore, pre-operative CBCT evaluation plays a critical role in minimizing implant positioning errors and enhancing surgical safety by enabling precise identification of neurovascular structures.

Recommendations for clinicians

Based on the findings of the present study, several practical recommendations can be proposed for clinicians performing procedures in the interforaminal region of the mandible.

preoperative CBCT assessment should be considered essential for implant planning to accurately identify the position of the mental foramen and the presence of any anterior loop.

clinicians should avoid relying on contralateral anatomical symmetry when determining the position of the mental foramen, as significant left–right asymmetry was observed in this study.

Although the prevalence of the anterior loop was relatively low, its mean extension of approximately 3 mm suggests that maintaining a safety margin of at least 5mm anterior to the mental foramen may help reduce the risk of mental nerve injury during implant placement or surgical procedures. These recommendations may contribute to safer surgical planning and improved patient outcomes.

Future Directions

Multicenter research with larger and more varied samples from Pakistan (urban/rural, various ethnic groups) to confirm prevalence and morphometry.

Association of AL presence/length with vertical and buccolingual bone measurements, alveolar ridge resorption, and mandible morphology.

Current imaging protocols (increased resolution, segmentation algorithms) to identify micro-loops or minor anterior extensions.

Prospective clinical correlation with neurosensory results in implant or surgical scenarios: does loop proximity really predict patient morbidity?

Limitations:

The sample size, while respectable ($n = 217$), was from one institution and cannot be assumed to generalize across all ethnic or regional subpopulations.

There were only six cases with bilateral measurable loops, which restricts power for paired comparisons.

Our criteria for deciding an AL (e.g. minimal anterior extension) and resolution of images (voxel size, slice thickness) could affect detection sensitivity.

We did not control for vertical height of bone, alveolar atrophy, or variation in mandibular shape, which some reports indicate could affect loop morphology.

Logistic regression accounted for a minority of variance; unmeasured anatomical, genetic, or developmental variables could have a greater influence.

Conclusion

This CBCT-driven investigation illustrated that in a Pakistani population, the mental foramen is most often found in Zones B and C, but with extreme left–right asymmetry, meaning that contralateral anatomy cannot be used to predict the position of the mental foramen. The anterior loop of the inferior alveolar nerve was relatively rare, but when present it was on average

extending approximately 3 mm. Loop length had no important correlation with side, age, or gender, and logistic regression established limited predictive potential of demographic and positional factors.

These results highlight the necessity of personalized CBCT assessment in the interforaminal area, especially for implant positioning, periapical surgery, and local anesthesia. Use of general anatomical standards or symmetry with the contralateral side can lead to unnecessary neurovascular risk for patients. Addition of preoperative CBCT to standard planning can improve surgical safety and the outcome of prosthodontic and implant dentistry.

Conflicts of interest: The authors declare no conflicts of interest.

Fundings: This research received no external funding.

Supplementary Results Tables

Table S1. Anterior loop prevalence by gender (N=217)

Gender	Both Sides N (%)	Right Only N (%)	Left Only N (%)	Absent N (%)	Total
Male	5 (5.8%)	12 (14.0%)	8 (9.3%)	61 (70.9%)	86
Female	1 (0.8%)	18 (13.7%)	8 (6.1%)	104 (79.4%)	131

Likelihood ratio $\chi^2=6.06$, $p=0.109$ (not significant).

Table S2. Anterior loop prevalence by age group (N=217)

Age Group	Both Sides N (%)	Right Only N (%)	Left Only N (%)	Absent N (%)	Total
16–30 years	2 (3.4%)	10 (16.9%)	6 (10.2%)	41 (69.5%)	59
31–45 years	1 (1.2%)	11 (13.8%)	8 (10.0%)	60 (75.0%)	80
46–60 years	3 (3.8%)	9 (11.5%)	2 (2.6%)	64 (82.1%)	78

Likelihood ratio $\chi^2=7.13$, $p=0.309$ (not significant).

Table S3. Anterior loop extension by gender and side

Side	Gender	N	Mean (mm)	SD (mm)	t(df)	p-value
Right	Male	17	2.84	0.64	-0.62(34)	0.539
Right	Female	19	2.98	0.66	-	-
Left	Male	13	3.10	0.59	-0.10(20)	0.920
Left	Female	9	3.13	0.56	-	-

Independent t-tests showed no significant gender differences. Levene's test $p>0.65$.

Table S4. Anterior loop extension by age group

Side	Age Group	N	Mean (mm)	SD (mm)	t(df)	p-value
Right	16–30 years	12	2.95	0.56	F(2,33)=0.027	0.974
Right	31–45 years	12	2.91	0.72	-	-
Right	46–60 years	12	2.89	0.70	-	-
Left	16–30 years	8	3.06	0.65	F(2,19)=0.887	0.428
Left	31–45 years	9	3.00	0.40	-	-
Left	46–60 years	5	3.40	0.68	-	-

One-way ANOVA: no significant age differences in loop extension.

Table S5. Stepwise logistic regression models for anterior loop presence

Model Step	Predictors Included	χ^2 (df)	p-value	Significant Predictors	Notes
Step 1	RMF, LMF, Gender, Age	-	>0.2	None	Initial full model
Step 2	RMF, LMF, Age	-	>0.15	None	Gender Dropped
Step 3	RMF, Age	$\chi^2(4)=5.59$	0.134	RMF(3) $p=0.022$	Final model, limited predictive power

Independent t-tests showed no significant gender differences. Levene's test $p>0.65$.

References

1. Zainab H, Sylvia S, Ahmed MK. Study of anatomical variations of mental foramen in dry adult human mandibles and its clinical importance in Karnataka population. *Indian Journal of Clinical Anatomy and Physiology*. 2020;7(3):327-30.
2. Habash G, Beshtawi KR, Jayash SN. Anatomical variant of anteriorly extending mental foramen: A case report. *Clinical Case Reports*. 2024;12(1):e8341.
3. Juodzbalys G, Wang H-L, Sabalys G. Injury of the inferior alveolar nerve during implant placement: a literature review. *Journal of oral & maxillofacial research*. 2011;2(1):e1.
4. Shaban B, Khajavi A, Khaki N, Mohiti Y, Mehri T, Kermani H. Assessment of the anterior loop of the inferior alveolar nerve via cone-beam computed tomography. *Journal of the Korean Association of Oral and Maxillofacial Surgeons*. 2017;43(6):395.
5. Jena S, Panigrahi R, Pati AR, Hasan S. Prevalence, patterns and variations of anterior loop of inferior alveolar nerve—A CBCT based retrospective study. *Indian Journal of Otolaryngology and Head & Neck Surgery*. 2022;74(Suppl 3):5424-31.
6. Gupta A, Kumar S, Singh SK, Kumar A, Gupta A, Mehta P. Assessment of anterior loop of inferior alveolar nerve and its anatomic variations with age, gender, and dentition status in Indian population: A CBCT study. *International Journal of Dentistry*. 2021;2021(1):1813603.
7. Mathew A, Mohan N. Prevalence, length, and patterns of Anterior Loop among the South Indian population: A comparative study between Panoramic Radiography and Cone Beam Computed Tomography. *Porto Biomedical Journal*. 2023;8(3):e216.
8. Pelé A, Berry P-A, Evanno C, Jordana F. Evaluation of mental foramen with cone beam computed tomography: a systematic review of literature. *Radiology research and practice*. 2021;2021(1):8897275.
9. Krishnan DT, Joylin K, Deepak JH, Ilango S, Al Hamad K, Shanab H, et al. Assessment of the anterior loop and pattern of entry of mental nerve into the mental foramen: a radiographic study of panoramic images. *Cureus*. 2024;16(3).
10. Shaikh SH, Ali A, Sultan D, Iqbal SN, Iyas Shaikh M, Shaikh S, et al. Determination of Anatomical Variation of Mental Foramen and Evaluation of Anterior Loop in Karachi Population Using CBCT. *Pakistan Journal of Medical & Health Sciences*. 2022;16(11):62-.
11. Ahmad M, Shabbir A, Ghazanfar S, Hassan H, Hassan H, ul Hassan A. Radiographic assessment of variability in position of mental foramen in relation to gender and age in local population of Punjab. *Biomedica*. 2024;40(4):170-5.
12. Ahmed AA, Ahmed RM, Jamleh A, Spagnuolo G. Morphometric analysis of the mandibular canal, anterior loop, and mental foramen: a cone-beam computed tomography evaluation. *International Journal of Environmental Research and Public Health*. 2021;18(7):3365.
13. Shalash M, Khallaf ME, Ali A. Position and dimensions of the mental foramen and presence of the anterior loop in the Egyptian population: a retrospective CBCT study. *Bulletin of the National Research Centre*. 2020;44(1):110.
14. Rahim S, Khan NH, Bilal S, Hanif N, Habib U, Haroon F. Prevalence and extent of anterior loop of the mandibular canal using cone beam computerized tomography. *Journal of Islamic International Medical College (JIIMC)*. 2021;16(4):243-7.
15. Guzmán J, Abarca J, Navarro P, Garay I, Arnabat-Domínguez J, Betancourt P. Morphometric analysis of the mandibular canal and its anatomical variants in a Chilean subpopulation: cone beam computed tomography study. *Diagnostics*. 2024;14(17):1914.
16. Alhudaithi A, Aljuailan AI, Alzaidan H, Almutairi F, Alrashaid AA, Kolarkodi SH. Patterns of Mental Foramen and Anterior Loop in Patients Attending Qassim University. A CBCT-based cross-sectional study. *Journal of Contemporary Dental Sciences*. 2025;2(1):34-42.
17. Al-Mahalawy H, Al-Aithan H, Al-Kari B, Al-Jandan B, Shujaat S. Determination of the position of mental foramen and frequency of anterior loop in Saudi population. A retrospective CBCT study. *The Saudi Dental Journal*. 2017;29(1):29-35.
18. Motiwala MA, Javed F, Ghafoor R. Cone Beam Computed Tomography based evaluation of position of mental foramen and its relation to apices of mandibular posterior teeth in a sample of Pakistani population. *JPMA The Journal of the Pakistan Medical Association*. 2022;72(10):1963-7.
19. Hui L, Hung KF, Bornstein MM, Leung YY. Assessment of the prevalence and length of the anterior and caudal loops of the mental nerve as anatomical variants of exiting the mandible at the mental foramen using cone-beam computed tomography: a systematic review and meta-analysis. *Clinical oral investigations*. 2022;26(11):6423-41.
20. Hadilou M, Gholami L, Ghojzadeh M, Emadi N. Prevalence and extension of the anterior loop of the mental nerve in different populations and CBCT imaging settings: A systematic review and meta-analysis. *Imaging Science in Dentistry*. 2022;52(2):141.
21. Srivastava S, Sethi KK, Sinha A, Srivastava A, Mishra A, Khan N, et al. Assessing the Prevalence and Length of the Anterior Loop of Inferior Alveolar Nerve and the Position and Dimension of Mental Foramen Using Cone Beam Computed Tomography. *Cureus*. 2024;16(9).

How to cite this article?

Kamran A., Zaigham A.M., Yaqub K., A cone beam computed tomography (CBCT) analysis of mental foramen location, prevalence of anterior loop and extension of anterior loop in the local population of Lahore: A cross-sectional study. J Rehman Coll Dent 2026; 7(1): 16-22

Author Contributions

1. Ali Kamran: Conceptualization, Study design, , Data Collection, radiographic analysis, Initial manuscript
2. Abdul Mueed Zaigham: Supervision, Critical Review
3. Khalid Yaqub: Study design, Data validation, statistical analysis, results iinterpretation results, Final manuscript